

# APPLICATION OF A NEW TYPE OF DISTRACTOR FOR AUGMENTATION OF THE ALVEOLAR RIDGE

Priv.-Doz. Dr. Dr. (H) A. Dunsche, Dr. Dr. M. Peuten, M. Pienkowski

In the last 25 years there have been many changes in dental implantology particularly in the field of restorative and prosthetic treatment options. Initially dental implants were inserted depending on the availability of bone, but this led to compromised function and aesthetics. Today preprosthetic surgery allows us to improve the bone and soft tissue situation giving better functional, prosthetic and aesthetic results. (pic.1, textbox: clinical methods of augmentation)

## Clinical methods of augmentation:

1. Transplantation von autologous bone
2. Use of bone augmentation- or bonesubstitutional material
3. Application of membranes likewise a „bone-guided-regeneration“
4. The distraction osteogenesis

Pic.1

The objective is to create adequate structural and biofunctional bone and soft tissues. Of all these available treatments osteodistraction of the alveolar ridge has become increasingly important during the last few years resulting in simultaneous augmentation of the bone and soft tissue.

These benefits may be affected through overcomplicated surgical handling leading to many complications so careful consideration must be given to Distractor design.

## MATERIALS AND METHOD:

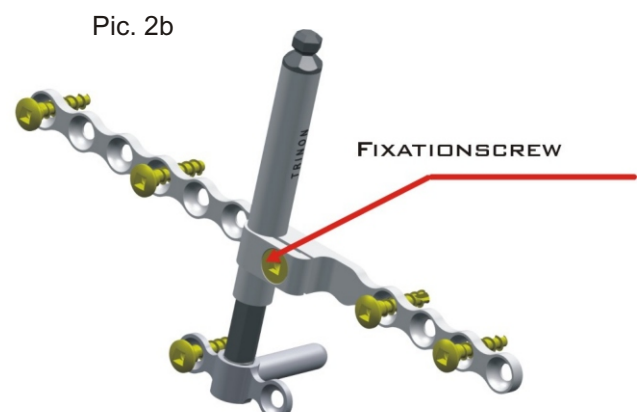

In Mund-, Kiefer- and Gesichtschirurgie Klinik (maxillofacial clinic) in Karlsruhe/Germany, 38 patients have been treated with distraction between 1999 and November 2003.

Initially the „LEAD-distractor“, an enosseus unit, and the „TRACK-distractor, an extraosseus system, were used. Since 2002 only modular distractors were used one from the company Medartis but more commonly the Q-MultiTractor type Karlsruhe, from TRINON Titanium, which was designed in cooperation with MKG Karlsruhe. This extraosseous, modular distraction system consists of three parts (pic.2).

1. baseplate
2. distractor spindle
3. transportation plate

Both plates (base and transportation) are available in different designs. A highlight is the pin plate (pic.2a) It consists of a pin of 2 mm diameter and 8 mm length, standing in a 90 degree angle to the distractor spindle. A hole for this pin has to be drilled close to the lower jaw rim and can be carried out with standard drills. To adjust the distraction vector a drilling guide has to be used, then the pin is inserted from the vestibulum in a lingual direction and finally fixed with two screws.

Pic. 2 Q-MultiTractor, type Karlsruhe with pin plate



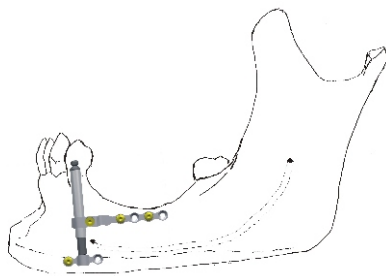
The adjustment of the pin in a bucco-lingual or bucco-palatal direction helps to avoid disorientation of the distraction vector during the distraction process. The stable and safe fixation of the baseplate through only three drill holes can be called minimally invasive. A precondition for using the pinplate is a minimal bone thickness of more than 8 mm; other modifications are advised if the bone is thinner than this.

Another advantage of the Q-MultiTractor is its modularity, which allows independent fixation of the spindle into the baseplate. Both elements are connected safely by means of a conical thread (pic.2a). The transportation plate is shifted onto the spindle and once fixed does not have to be removed again.

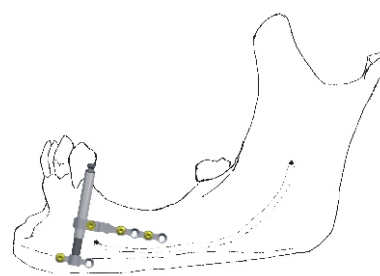
After loosening the fixing screw (pic. 2b) at the transportation plate the spindle can be withdrawn, while both plates stay in their chosen position. Horizontal bonecutting is carried out using the transportation plate as a guide.

After refixing the spindle the vertical bone cuts are made with a disc or Lindemann-drill. These cuts should have a 45 degree angle to facilitate bone block movement.

In particular, this is important with local atrophies in lateral areas. In these cases it was favourable to tilt the distraction vector 10° to the mesial to make sure that the horizontal bonecut along the transportation plate shows in the distal direction and prevents injuries to the nervus alveolaris inferior (pic. 3a, 3b).

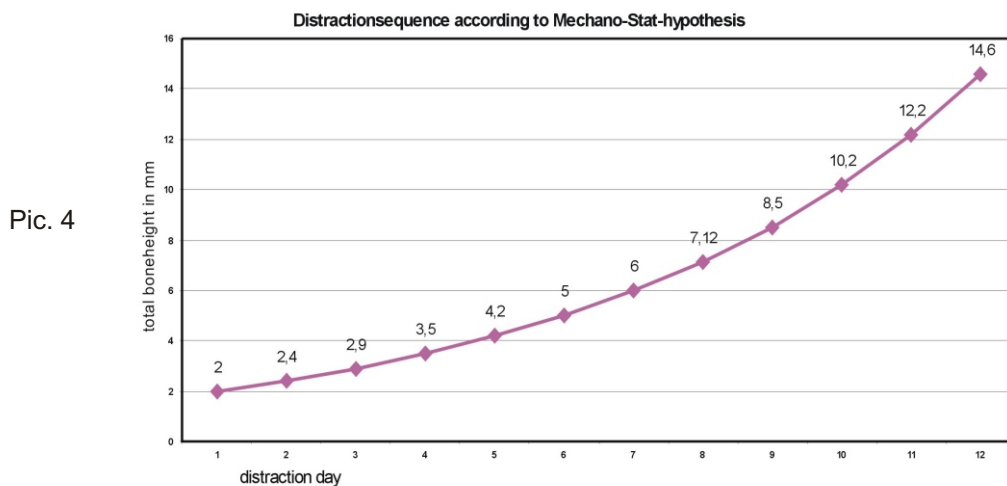


Pic. 3a right distraction vector in lateral areas



Pic. 3b wrong distraction vector in lateral areas

Double layer closure of the soft tissues completes the procedure. 8 days post surgery the distraction starts distracting 4-6 times daily. Operational sequence see picture 4.



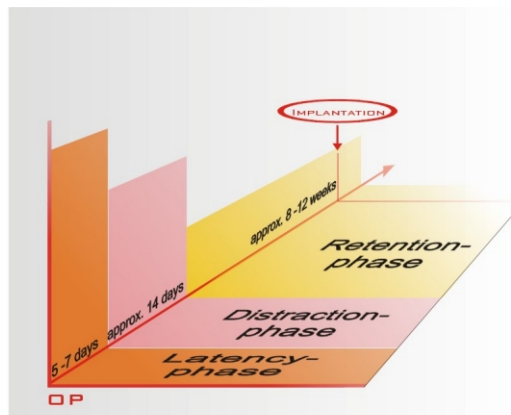
This operational sequence shows that at the beginning of the distraction the daily won boneheight is smaller and increases during distraction phase.

At the end of the distraction procedure, the fixing screw (pic.2b) is loosened through a minor incision at its position with the transportation plate just enough to lower the spindle under the gingiva and then refixed. Thus avoiding irritation to the gum during retention phase.

6-8 weeks later the fixing screw (pic.2b) is loosened again a little to achieve a minimal strain onto the callus through chewing-movements in the sense of a dynamising effect that influences the calcification process.

In general transportation plate is detached 10 weeks later, while the base plate remains untouched. Implantation takes place immediately or 14 days after detachment, trying to fix the implant through the new won callus into the base segment.

Operational sequence between operation und implantation demonstrates picture 5.

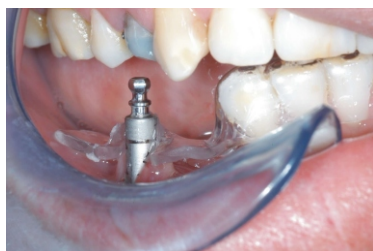

Pic. 5 Operational sequence

## RESULTS:

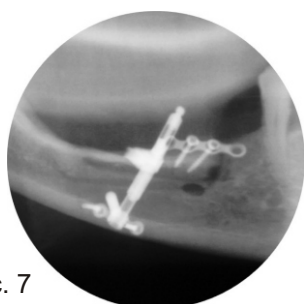
Since May 2003 nine Q-MultiTractor distractors have been inserted in ten patients.

Normally no complications, especially no wound healing problems, appeared during the distraction phase. In those 6 patients where we had used the pin-baseplate, the distraction vector did not misalign in bucco-lingual or bucco-palatal direction. This we inspected by moulding a 2mm thick foil in the partially dentate patients and milling the distraction vector immediately after the operation (pic.6). Weekly controls with the mask (moulded foil) showed no aberrations of the distracton vector. In 3 totally atrophic patients using the long baseplate, we contolled the lingualisation by means of ( **Ferrnröntgenseitenbild**) **special type of XRAY**

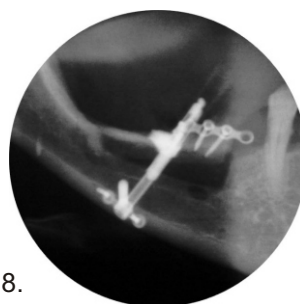


Pic. 6

In total, distraction was completed in 7 patients. In all cases the bone height that we were aiming for was reached. It ranged between 6 mm and 12 mm; average 8,5mm (pic.7,8)

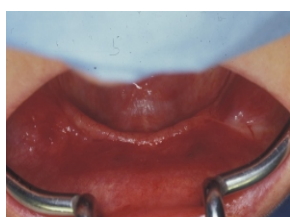


Pic. 7

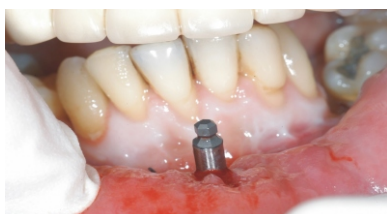

Pic. 8.

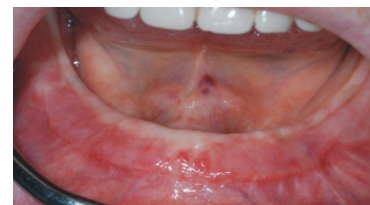Two of these 3 patients with total atrophy, are already fitted with implants, in this case Q-Implant® from Triron Titanium GmbH. After the integration phase of 2 months the final removable prosthesis with telescopic galvanocrowns, was completed (pic. 9-14).



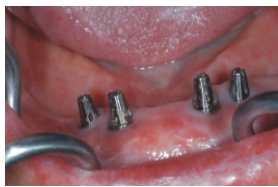Pic. 9 initial situation



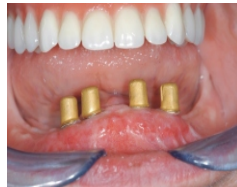Pic. 10 distraction phase



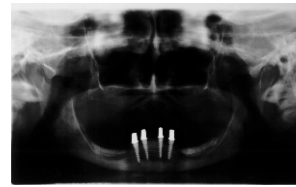Pic. 11 distraction end



Pic. 12 healing phase



Pic. 13 prosthesis care



Pic. 14 x-ray control

All 8 implants osseointegrated. Exploration depth after a healing phase of 2 months was 1,6 mm. No bleeding occurred while probing the sulcus. We are currently unable to comment on peri-implant bone loss due to short follow up period.

## DISCUSSION

In recent years vertical distraction of the atrophic alveolar ridge has established itself as a recognised pre-prosthetic bone augmentation method. The advantage is in remodelling of autologous bone and soft tissue simultaneously while avoiding the need to harvest bone grafts.

As previously mentioned uncomfortable and time consuming handling of most available distraction systems on the market diminish these advantages. Modular distraction systems, especially the latest evolution, Q-MultiTractor, solve many of these problems.

Many publications report a lack of stability of the distraction vector. Through the lingual / palatal pull of the periosteum there is always a risk that the distracted bone segment may tilt over. Various techniques have been tried to solve this problem.

The Q-MultiTractor with its pin-baseplate provides substantial stability by inserting the pin perpendicular to the distraction vector and being framed by bone in the bucco-lingual direction.

Historically to guarantee sufficient retention of the baseplate, wide sections of the bone had to be exposed to fix a long plate with many screws. The pin-baseplate feature reduces this to a small area close to the lower jaw rim only. Stable fixation is achieved with only 3 drill holes; one, as already mentioned, to insert the pin and stabilise in a bucco-lingual direction, and the other two holes are drilled for the fixation screws left and right of the pin, stabilising the mesio-distal direction (pic. 2a). therefore this operation can be called minimally invasive.

The difficulty in compound distractors is the temporal test fixing of the complete system to mark out the bone dissection level and re-fixation after the bone is cut.

Modular systems, like the Q-MultiTractor, allow definitive fixation of base and transportation plate, because the spindle can be withdrawn to carry out the horizontal, and screwed back inside to carry out the vertical bonecuts, the boneblock stays in situ all of the time and will not move. During the retention phase the distraction spindle can be reduced to 12 mm by countersinking it under the gingiva, leading to high acceptance by patients.

As previously mentioned our distraction steps refer to the results of „Mechano-Stat“-theory of Frost et al. According to this hypothesis, bone is remodelled if distraction occurs in the range of 2.000 and 5.000 microstrain. Microstrain indicates the relation of the bonegap before and after distraction and therefore has no dimension. At the start of distraction this gap is approx. 1 mm and therefore minor distraction stretch is advisable. The larger the bone gap the higher the daily distraction stretch (pic.4).

We are conscious of deviating from common distraction methods, distracting the same daily distance during the whole procedure but results to date support our methodology.

Re-ossification of the callus has been reported in many publications. Q-MultiTractor makes a significant contribution to this subject. Loosening the fixation screw on the transportation plate -being the only connection between transportation plate and spindle transfers minimal force impact while opening and closing the mouth. Publications of Jost et al. report that forces of 1000 microstrains are activated during these movements. When these effects are transferred to the distractor the process leads to stimulation of the bone.

Another advantage of the minimally invasive method is to remove the spindle and transportation plate, without having to touch the newly built tissues. The baseplate can be removed later, the pinplate can even remain in situ.

In summary we can state that the Q-MultiTractor significantly improves upon existing distraction devices and consequently will lead to an expansion of this pre-prosthetic augmentation method.

Dr. Dr. Matthias Peuten  
Direktor, Priv.-Doz. Dr. Dr.(H) Anton Dunsche  
Klinik für Mund, Kiefer- und Gesichtschirurgie, Karlsruhe  
Plastische, rekonstruktive und ästhetische Gesichtschirurgie  
Zahnärztliche Ambulanz  
Moltkestr. 120  
76133 Karlsruhe

Mirosław Pienkowski  
Trinon Titanium GmbH  
Augartenstr. 1  
76137 Karlsruhe

#### Literature

1. Frost HM. Strain and other mechanical influences on bone strength and maintenance. Curr Opin Ortho 1997;8:60-70